



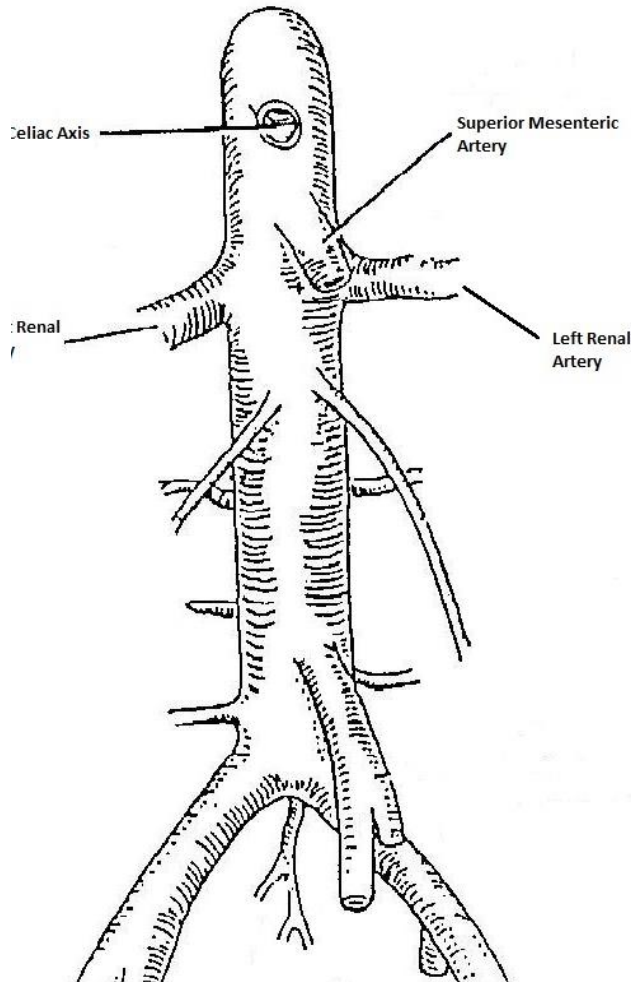
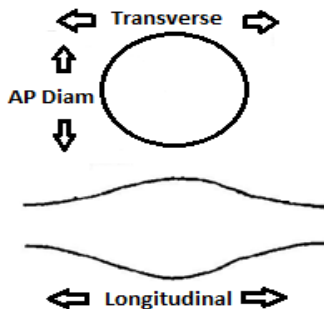
CARDIORISK AAA SCREENING

Patient Name: ALTMANN, STEVEN Date: 12-08-2023

DOB: 03/24/1949 Sex: M

Referring Provider: NISHANT MAGAR

Vascular Technician: MICHELE WALTERS



Aorta Prox

N/V cm Trans X N/V cm AP

Aorta Mid

2.1 cm Trans X 2.2 cm AP

Aorta Distal

2.1 cm Trans X 2.0 cm AP

Comments: Limited visibility of the Abdominal Aorta due to overlying bowel gas. Unable to exclude the possibility of an Abdominal Aortic Aneurysm in the non-visualized portion(s) of the Abdominal Aorta. No plaque identified in the submitted images. Suggest future abdominal ultrasound imaging be attempted early in the day, with strict NPO status of 6-8 hours and consider OTC gas medication, unable to visualize any of the proximal segment of the abdominal aorta due to extensive overlying bowel gas.



